

Endoscopic Ultrasound: Accuracy in Staging Superficial Carcinomas of the Esophagus

Sabrina Rampado, MD, Paolo Bocus, MD, Giorgio Battaglia, MD, Alberto Ruol, MD, FACS, Giuseppe Portale, MD, and Ermanno Ancona, MD, FACS

Department of Gastroenterological and Surgical Sciences, Clinica Chirurgica III, University of Padova School of Medicine and the Istituto Oncologico Veneto (IOV-IRCCS), Padova, Italy

Background. Endoscopic procedures may represent an alternative to esophagectomy for superficial neoplasms of the esophagus (T1m/T1sm), but they are considered curative only in case of no lymph node involvement. Endoscopic ultrasound (EUS) is the most accurate method to define both T and N staging of esophageal carcinoma. Aims of the study were to assess the staging accuracy of EUS in superficial lesions (T1m and T1sm) of patients who were candidates for esophagectomy or local endoscopic resection and to establish which variables (site of neoplasm, histologic type, macroscopic appearance) can affect the accuracy of EUS in distinguishing between T1m and T1sm lesions.

Methods. The study population consisted of 55 patients with superficial carcinoma of the esophagus who underwent EUS (October 2002 to January 2007). Endoscopic ultrasound features were compared with findings from surgical specimens or samples obtained at mucosectomy.

Results. There were 33 patients with adenocarcinoma (60%), which developed on Barrett's esophagus in 27 cases, 21 patients (38%) with squamous cell carcinoma, and 1 (2%) with lymphoepithelial-like carcinoma. All lesions were confirmed as T1 on pathology. Of the 22 (40%) T1m lesions on EUS, 19 (86%) were confirmed as

T1m on pathology; of the 33 T1sm on EUS, 22 (66%) were confirmed as T1sm. Positive predictive value of EUS for invasion of the submucosa was 67%, negative predictive value 86%, sensitivity 88%, specificity 63%, and diagnostic accuracy 75%. The accuracy of EUS in evaluating lymph node metastases was 71%, with a negative predictive value of 84%. Endoscopic ultrasound accuracy in differentiating mucosal from submucosal lesions increased from the lower esophagus or gastroesophageal junction to the mid and upper esophagus (71%, 76%, and 100%, respectively; not significant). As for the histologic type, accuracy was 70% for adenocarcinoma and 81% for squamous cell carcinoma, (not significant); for lesions detected as type 0-IIa (13 patients), accuracy was 100%; for type 0-I lesions (23 patients), accuracy was 70% ($p = 0.03$).

Conclusions. Despite difficulties in differentiating mucosal from submucosal lesions, even with 20-MHz mini-probes, EUS remains an extremely valuable tool when nonsurgical treatments are considered. Its staging accuracy depends on site and macroscopic appearance of the neoplasm.

(Ann Thorac Surg 2008;85:251–6)

© 2008 by The Society of Thoracic Surgeons

Endoscopic procedures may represent an alternative to esophagectomy for superficial neoplasms (T1) or high-grade dysplasia of the esophagus [1]. Endoscopic treatments are considered curative in T1 esophageal carcinoma, when lymph nodes are not involved by the disease. The chances of identifying lymph node metastases before surgery are low, however [1]. Therefore, so far, esophageal resection with lymph node dissection is considered the standard curative treatment.

Several factors, however, have stimulated interest in alternative, nonsurgical treatment options: the natural history of high-grade dysplasia is variable: in some patients it remains stable for long periods, whereas in others it can evolve toward invasive disease in a relatively short time frame [2]. Esophagectomy suffers from high mortality and morbidity rates. Furthermore, many

patients are not suitable candidates for surgery because of comorbidities.

The presence of lymph node metastases is strictly related to the depth of tumor infiltration in the esophageal wall. This means that it is negligible when the carcinoma is limited to the mucosa but reaches 20% to 30% in case of submucosal invasion. Distinguishing between superficial carcinoma (limited to the mucosa, T1m) and more advanced ones infiltrating the submucosa (T1sm and higher) is crucial to select patients for local endoscopic resection. Endoscopic ultrasound (EUS) provides a detailed image of the esophageal wall and is the most accurate means available to date for staging esophageal carcinoma, in terms of both depth of invasion (T stage) and presence or absence of lymph nodes (N stage).

The aims of this study were to assess the diagnostic accuracy of EUS in identifying the more superficial lesions (T1m and T1sm) in patients undergoing esophagectomy or local endoscopic resection, and to establish whether certain variables (site of neoplasm, histologic type, macroscopic appearance) can influence the diag-

Accepted for publication Aug 9, 2007.

Address correspondence to Dr Battaglia, Istituto Oncologico Veneto (IOV-IRCCS), University of Padova School of Medicine, Via Giustiniani 2, Padova, 35128, Italy; e-mail: giorgio.battaglia@unipd.it.

Table 1. Classification of Variables Related to Endoscopic Ultrasound Accuracy in Distinguishing Mucosal From Submucosal Lesions

Variable	Classification
Site	Esophagus: upper/mid/lower + gastroesophageal junction
Histologic type	SCC/Adenocarcinoma/Other
Macroscopic appearance ^a	0-I; 0-IIa; 0-IIb; 0-IIc; 0-III

^a Paris classification: type 0-I = superficial protruding lesion; 0-IIa = slightly elevated; 0-IIb = flat; 0-IIc = slightly depressed; 0-III = excavated.

nostic accuracy of EUS in distinguishing mucosal from submucosal lesions.

Patients and Methods

From October 2002 to January 2007, 450 patients with carcinoma of the esophagus or gastroesophageal junction underwent EUS: 55 (5.8%) of them were staged as superficial carcinomas (T1m or T1sm) on EUS.

The endoscopic features of the tumor were assessed in all patients (ie, site and macroscopic appearance; **Table 1**), as were the ultrasound findings (including EUS staging), the histopathologic findings, and, for patients undergoing operation, the pathologic staging.

The staging accuracy of EUS, in terms of distinguishing mucosal from submucosal lesions, was evaluated in relation to the site of the neoplasm, to its histologic type, and to its macroscopic appearance (according to the Paris endoscopic classification [3]; **Table 1**).

The EUS features were compared with the surgical specimen or the sample obtained on mucosectomy. The accuracy of EUS in establishing the presence or absence of lymph node metastases was only assessed in patients who underwent surgery. None of the patients had previously received chemotherapy or chemoradiotherapy.

The study was approved by the Ethics Committee of the University of Padova Medical School. Given that individual patients could not be identified, the need for patient consent was waived.

Endoscopic Ultrasound

Endoscopic ultrasound was performed under conscious sedation with benzodiazepine in 31 patients (56%), whereas propofol was used in 19 patients (35%) and a local oropharyngeal anesthetic was used in 5 patients (9%). All EUS procedures were performed by the same expert endoscopist, using an operative (Olympus GIF 130T) or dual-channel (Olympus 2T160) endoscope to allow for the passage of the miniprbes and the injection of water directly with a pedal pump (pressure-controlled and temperature-controlled system), with 12- and 20-MHz miniprbes (Olympus UM-2R/3R, Tokyo, Japan), both in all patients.

Patients lay supine on their left side, with their shoulder raised in an anti-Trendelenburg position. In the event of proximal esophageal lesions, a soft silicone

overtube was used to prevent any aspiration of water into the airways. No complications were recorded.

The integrity of the hyperechogenic third sonographic layer, or the interface between the second and third layer underneath the lesion, excluded an invasion of the submucosa. Lesions with these features were classified as T1m. Invasion of the submucosa (T1sm) was diagnosed when there was evidence of hypoechogenic destruction of the interface between the second and third sonographic layers or hypoechogenic focal thickening of the third layer.

Lymph node staging was completed in all cases. The lymph node status was assessed on the full length of the esophagus and also in the proximal and celiac gastric region. Lymph nodes were considered positive (N1) when two of the following criteria were met: lymph node size greater than 5 or 10 mm, hypoechogenic, with rounded shape and with clearly defined margins. According to Bhutani and colleagues [4], when all four of these variables are present, accuracy in predicting lymph node involvement is close to 85%. A lymph node was considered not involved (N0) if it was small, isoechogenic or hyperechogenic, with poorly defined margins, and not rounded in shape. Endoscopic ultrasound-guided fine-needle aspiration (FNA) biopsy was not performed in patients considered in the present analysis because it was not available until early 2007.

Patients were considered eligible for endoscopic treatment if the superficial lesion was up to a diameter of 20 mm in case of well-differentiated nondepressed lesions, and up to 10 mm in case of depressed lesions [3]. Treatment choice was also based on the patients' conditions (severe comorbidities, refusal for surgery, clear lymphadenopathy).

Patients undergoing curative mucosectomy were followed up with endoscopy at 1 month (with biopsies on and around the scar, to make sure that there were no other foci of neoplastic disease), and then with endoscopy and EUS at 6, 12, 18, and 24 months.

Table 2. Demographics and Clinical Features

Characteristics	Absolute Number (%)
Sex (M/F)	46 (84%)/9 (16%)
Median age, y (interquartile range)	67 (59-72)
Site of neoplasm	
Upper third	3 (5%)
Mid third	17 (31%)
Lower third - gastroesophageal junction	35 (64%)
Histology	
Squamous cell carcinoma	21 (38%)
Adenocarcinoma	33 (60%)
Other	1 (2%)
pT1 stage (m/sm)	30 (55%)/25 (45%)
pN stage (pN0/N1)	33 (87%)/5 (13%)
Type of resection	
Endoscopic mucosal resection	17 (31%)
Surgical resection	38 (69%)

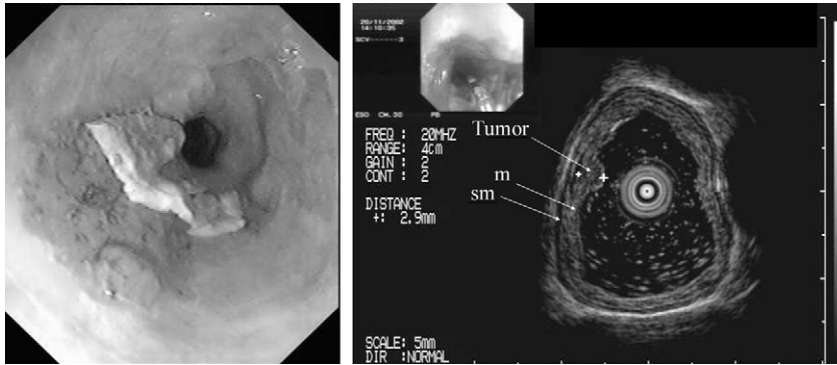


Fig 1. Early mucosal adenocarcinoma in Barrett's esophagus. Endoscopic view (left) shows small slightly elevated lesion of the lower third of the esophagus (type 0-IIa). Endoscopic ultrasonography with 20-MHz mini-probe (right) shows the small, slightly elevated lesion, homogeneous on echo, with circumscribed thickening of the mucosa. Pathologic examination revealed a T1m lesion (mucosectomy). (m = mucosa; sm = submucosa.)

Histopathologic Assessment

Surgical specimens and samples obtained on mucosectomy were analyzed according to a standard method: the tissues were fixed in 5% formalin and the area of tumor and adjacent normal tissue were embedded in paraffin. Sections 5 μ m thick were cut from each block and stained with hematoxylin and eosin.

Based on the 6th edition of the TNM classification of malignant tumors [5], T1 carcinomas were further classified as T1a or T1m (limited to the mucosa or to the muscularis mucosae) and T1b or T1sm (extending to the submucosa).

Surgery and Local Endoscopic Resection

Thirty-eight patients (69%) underwent esophagectomy: the Ivor-Lewis or McKeown method was used in 35 patients (92%) means of a transthoracic approach, with standard lymphadenectomy extending to two levels, and esophagogastropasty; the transhiatal approach was used in 3 patients (8%), with esophagojejunoplasty in 1 patient. Seventeen patients (31%) underwent endoscopic mucosectomy without lymphadenectomy.

Mucosectomy is defined as the resection of a fragment of the digestive tract wall, including the mucosa, the muscularis mucosae, and all or part of the submucosa [6]. The technique is called "suck and cut" and has four steps: to mark the lesion at the four cardinal points with a closed diathermal loop; to inject saline solution to detach

the mucosa and submucosa from the muscularis propria; to aspirate the lesion inside a hood, while applying an elastic ring to the base of the lesion, which is resected with a diathermal loop. Alternatively, the lesion can be lifted, aspirated inside a hood and resected directly with a diathermal loop. At the end of the procedure, biopsies are taken from the fundus and at the margins of the mucosectomy.

Statistical Analysis

Data are expressed as median and interquartile ranges. Fisher's exact test was used to compare categorical data. A probability value of less than 0.05 was considered significant.

Results

Clinical and pathologic findings are summarized in Table 2. Our study population of 55 patients included 46 men (84%) and 9 women (16%), with a median age of 67 years (interquartile range, 59 to 72). The neoplasm was located in the upper thoracic esophagus in 3 patients (5%), in the mid thoracic esophagus in 17 patients (31%), and in the lower thoracic esophagus or gastroesophageal junction in 35 patients (64%).

The prevalent histologic type was adenocarcinoma in 33 patients (60%) [27 of these (82%) had Barrett's esophagus]. Twenty-one patients (38%) had squamous carci-

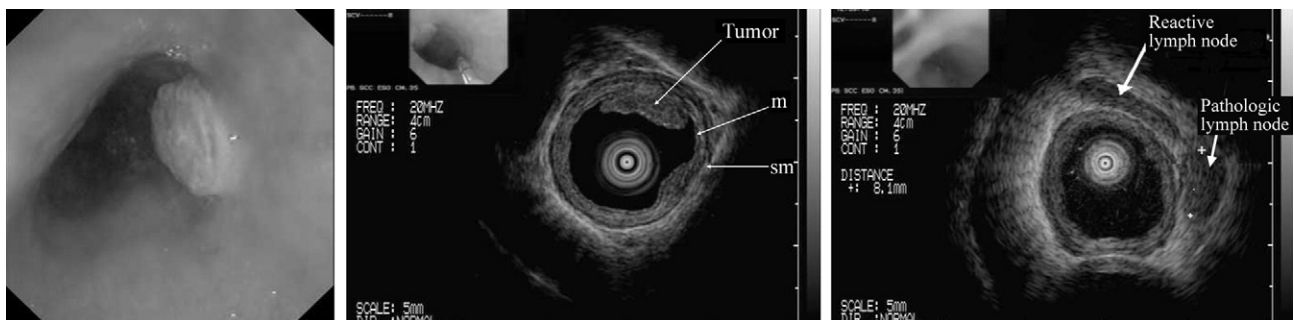


Fig 2. Early submucosal squamous carcinoma of the esophagus. Endoscopic view (left) shows nodule of the lower third of the esophagus (type 0-I). Endoscopic ultrasonography with 20-MHz miniprobe (center, right) shows mucosal and submucosal thickening. On pathologic examination (esophagectomy) it was a T1sm squamous carcinoma. One suspected (rounded shape, clearly defined margins, hypoechoogenicity) lymph node (arrow) for metastatic involvement; another, probably reactive (thick arrow). (m = mucosa; sm = submucosa.)

Table 3. Accuracy of Endoscopic Ultrasound in Revealing Presence or Absence of Submucosal Invasion in Patients With Superficial Carcinoma of the Esophagus

EUS Finding	Pathology (n = 55)	
	SM Involvement	No SM Involvement
SM involvement (n = 33)	22	11
No SM involvement (n = 22)	3	19

EUS = endoscopic ultrasound; SM = submucosal.

noma, and 1 patient (2%) had lymphoepithelial-like carcinoma.

All 55 patients staged as T1 at EUS were confirmed as T1 on pathology, with a 100% diagnostic accuracy of EUS in distinguishing T1 lesions from a more advanced stage of disease (T2 and beyond).

On EUS, 22 of the 55 patients (40%) had an uninterrupted third layer, suggesting no invasion of the submucosa (stage T1m; Fig 1). Signs of hypoechogenic disruption of the third layer (stage T1sm) were recorded in 33 of 55 patients (60%; Fig 2, center).

Histopathologic examination of the surgical specimens revealed high-grade dysplasia or intramucosal carcinoma (pT1m) in 30 of 55 cases (55%) and submucosal carcinoma (pT1sm) in 25 of 55 cases (45%).

The accuracy of EUS in identifying invasion of the submucosa is shown in Table 3. Absence of submucosal invasion was confirmed in 19 of 22 patients (86%) staged T1m on EUS, whereas 22 of 33 patients (66%) showing submucosal lesions on EUS were confirmed T1sm on pathology. The positive predictive value of EUS for submucosal invasion was 67%, the negative predictive value was 86%, the sensitivity was 88%, and the specificity was 63%. Its diagnostic accuracy was 75%.

Of the 38 patients undergoing esophagectomy, 6 (16%) met the criteria for lymph node metastasis at EUS (Fig 2, right), and 5 (83%) revealed invasion of the submucosa at EUS. On pathologic staging, 5 of 38 patients (13%) had lymph node metastases (Table 4). The median number of lymph nodes examined was 16 (interquartile range, 12 to 21).

The accuracy of EUS in identifying lymph node involvement is given in Table 4. Its negative predictive value was 84%, with a diagnostic accuracy of 71%. As for the site of the lesion, the accuracy of EUS in differentiating between mucosal and submucosal lesions increased from the lower third of the esophagus and gastroesophageal junction to the mid and upper third of the esophagus (71%, 76%, and 100%, respectively; not significant). As for the histologic type, the diagnostic accuracy of EUS was 70% for adenocarcinoma and 81% for squamous cell carcinoma (not significant).

Macroscopic appearance was another important variable in case of type 0-IIa lesion (13 patients); the diagnostic accuracy was 100%, although this dropped to 70% for nodular lesions, type 0-I (in 23 patients; $p = 0.03$).

Comment

To date, EUS is considered the best technique available to define locally advanced potentially curable lesions in patients with carcinoma of the esophagus and gastroesophageal junction. In the present study, its negative predictive value was 86% for T staging and 84% for N staging. Other studies have reported values close to 100%: Buskens and associates [7] found a negative predictive value of 95% for submucosal invasion and 93% for lymph node involvement, and Scotiniotis and coworkers [2] reported a negative predictive value of 100% for both submucosal invasion and lymph node involvement. Our data confirm the difficulty of distinguishing tumors invading the mucosa from those infiltrating the submucosa. This is an important step before choosing a nonsurgical therapeutic approach. The risk of lymph node metastases increases from 3%–6% for mucosal lesions to 21%–24% for submucosal lesions [8, 9]. This tenfold difference probably is related to the rich lymphatic network of the submucosa. This is the reason why local endoscopic treatments should not be considered for patients with submucosal invasion. Endoscopic ultrasound is an extremely valuable tool in selecting patients for endoscopic treatment. In the present study, it identified 19 of 55 T1m lesions (35%), ie, cases amenable to endoscopic treatment. Endoscopic ultrasound overestimated the T stage in 11 of 55 patients (20%)—5 of these (45%) had nodular lesions—and underestimated the N stage in 6 of 38 patients (16%). Endoscopic ultrasound underestimated the T stage in 3 of 55 patients (5.5%) and the N stage in 5 of 38 patients (13%).

Endoscopic ultrasound findings should consequently be interpreted with caution, especially in case of nodules or protruding lesions, which can negatively affect the reliability of the method (the diagnostic accuracy of EUS dropped in our series from 100% for type 0-IIa lesions to 70% for type 0-I lesions). Based on experience with EUS in a series of patients with Barrett’s esophagus and dysplasia, Falk and colleagues [10] suggested that nodularity of the mucosa contributed to lesion overstaging, probably as a result of the altered pattern of the sonographic layer from inflammatory changes.

Overstaging can be attributed to the following factors [11]: (1) peritumoral inflammation, which leads to wall thickening, making the different layers less easily distinguishable; (2) inappropriate positioning of the ultrasound transducer, causing a pseudothickening and a poor view of the layers (a problem overcome by the use of mini-

Table 4. Accuracy of Endoscopic Ultrasound in Defining Presence or Absence of Lymph Node Metastases in Patients With Superficial Carcinoma of the Esophagus

EUS Finding	Pathology (n = 38)	
	N0	N1
N0 (n = 32)	27	5
N1 (n = 6)	6	—

EUS = endoscopic ultrasound.

probes); and (3) massive invasion of the submucosa, which can reduce the thickness of the hyperechogenic medial layer to the point where it becomes unrecognizable. The accuracy of EUS in differentiating mucosal from submucosal lesions drops progressively from the upper esophagus toward the gastroesophageal junction; this is attributable to technical problems: it is more difficult to create an acoustic interface at the gastroesophageal junction unless the instruments used are fitted with a balloon, but this poses problems of pressure applied to the mucosa.

Miniproboscopes that pass through the endoscopic operating channel have been developed to assess superficial lesions of the gastrointestinal tract. The potential advantages of these devices include a higher definition, owing to their high frequency and positioning under direct endoscopic guidance. The images obtained with high-frequency probes afford an excellent view of the wall, revealing up to nine layers in the esophagus [12]. Compared with standard EUS, miniproboscopes reveal a greater diagnostic accuracy for T staging [12] for the muscularis mucosae (100%), the submucosa (83%), and the muscularis propria (100%) [13]. Cases of superficial carcinoma appear as a focal thickening, restricted to the first two (T1m) or three layers (T1sm) [12]. In a Japanese study [14], 96 lesions were staged using miniproboscopes, revealing an accuracy of 93% in differentiating between mucosal and submucosal lesions. In our series, its diagnostic accuracy was only 75%, confirming the difficulty in distinguishing mucosal from submucosal lesions, as reported by May and associates [15], who calculated a staging accuracy of 79.6% (74 of 93 patients) for high-resolution EUS.

Endoscopic mucosectomy remains a valid preoperative staging method, which becomes a curative treatment in cases of intramucosal lesions included entirely in the resection margins. When there is evidence of submucosal involvement, however, mucosectomy cannot be considered a definitive treatment, and surgery or chemoradiotherapy (for unfit patients or for those refusing surgery) is recommended [16]. As for the accuracy of EUS in determining malignant adenopathy associated with esophageal carcinoma, this varies from 50% to 70% [17, 18], and miniproboscopes are less accurate for N-staging purposes than standard EUS.

In our study, the negative predictive value was 84%, and the diagnostic accuracy was 71%, as reported in the literature. According to Shami and coworkers [19], a lymph node is highly suspect when two of the following ultrasound criteria are met: a rounded shape, clearly defined margins, and hypoechoic. Size cannot be considered a criterion to rule out malignancy, however; in fact, two of five pathologic lymph nodes were less than 1 cm in size. Combining needle aspiration with EUS can increase its diagnostic accuracy: in 20% of patients, EUS and needle aspiration prompted a change in the treatment choice. The results obtained using this approach cannot be compared with the histopathologic analysis of the surgical specimen, however.

In conclusion, EUS is an extremely useful tool when

considering emerging nonsurgical treatments that can be effective alternatives to esophagectomy in patients with superficial carcinoma of the esophagus who refuse surgery or are unsuitable candidates for esophagectomy because of comorbidities. So far, however, it remains extremely difficult to differentiate between mucosal and submucosal lesions, even using high-frequency miniproboscopes. In our study, we used 12- and 20-MHz miniproboscopes; 30-MHz miniproboscopes seem to improve accuracy, but further studies are needed to confirm this finding. The diagnostic accuracy of EUS depends on the site of the neoplasm: it increases progressively from the gastroesophageal junction toward the upper esophagus, where it is 100% accurate. It is also influenced by the macroscopic appearance of the lesion: it is greatest if the lesion is slightly elevated (0-IIa) and declines if the lesion is protruding or nodular (type 0-I; $p = 0.03$). Histologic type (squamous cell carcinoma or adenocarcinoma) does not significantly affect the accuracy of EUS in T staging, and is greater for squamous cell carcinoma. Finally, for best diagnostic accuracy, we recommend using miniproboscopes for T staging and 7.5- to 12-MHz probes in combination with fine needle aspiration in case of suspected lymph nodes for N staging.

References

1. Bollschweiler E, Baldus SE, Schroder W. High rate of lymph-node metastasis in submucosal esophageal squamous-cell carcinomas and adenocarcinomas. *Endoscopy* 2006;38:149–56.
2. Scotinotis IA, Kochman ML, Lewis JD, et al. Accuracy of EUS in the evaluation of Barrett's esophagus and high-grade dysplasia or intramucosal carcinoma. *Gastrointest Endosc* 2001;54:689–96.
3. Endoscopic classification review group. Update on the Paris endoscopic classification of superficial neoplastic lesions in the digestive tract. *Endoscopy* 2005;37:570–8.
4. Bhutani MS, Hawes RH, Hoffman BJ. A comparison of the accuracy of echo features during endoscopic ultrasound (EUS) and EUS-guided fine-needle aspiration for diagnosis of malignant lymph node invasion. *Gastrointest Endosc* 1997;45:474–9.
5. Sobin LH, Wittekind CH. UICC: TNM classification of malignant tumors, 6th ed. New York: Wiley-Lis; 2002.
6. Greff M, Palazzo L, Ponchon TH. Guidelines of the French Society of Digestive Endoscopy: endoscopic mucosectomy. *Endoscopy* 2001;33:187–90.
7. Buskens C, Westerterp M, Lagarde M, et al. Prediction of appropriateness of local endoscopic treatment for high-grade dysplasia and early adenocarcinoma by EUS and histopathologic features. *Gastrointest Endosc* 2004;60:703–10.
8. Sabik JF, Rice TW, Goldblum JR, et al. Superficial esophageal carcinoma. *Ann Thorac Surg* 1995;60:896–902.
9. Ban S, Mino M, Nishioka NS, et al. Histopathologic aspects of photodynamic therapy for dysplasia and early adenocarcinoma arising in Barrett's esophagus. *Am J Surg Pathol* 2004;28:1466–73.
10. Falk GW, Catalano ME, Sivak MV, et al. Endosonography in the evaluation of patients with Barrett's esophagus and high-grade dysplasia. *Gastrointest Endosc* 1994;40:207–12.
11. Souquet JC, Napoleon B, Pujol B, et al. Echoendoscopy prior to endoscopic tumor therapy—more safety? *Endoscopy* 1993;25:475–8.

12. Isenberg GA. Catheter-probe-assisted endoluminal US. *Gastrointest Endosc* 2004;60:608-22.
13. Murata Y, Suzuki S, Ohta M, et al. Small ultrasonic probes for determination of the depth of superficial esophageal cancer. *Gastrointest Endosc* 1996;44:23-8.
14. Kawano T, Ohshima M, Iwai T. Early esophageal carcinoma: endoscopic ultrasonography using the Sonoprobe. *Abdom Imaging* 2003;28:477-85.
15. May A, Gunter E, Roth F, et al. Accuracy of staging in early oesophageal cancer using high resolution endoscopy and high resolution endosonography: a comparative, prospective, and blinded trial. *Gut* 2004;53:634-40.
16. Fujita H, Sueyoshi S, Yamana H, et al. Optimum treatment strategy for superficial esophageal cancer: endoscopic mucosal resection versus radical esophagectomy. *World J Surg* 2001;25:424-31.
17. Rosh T. Endosonography staging of esophageal cancer. *Gastrointest Endosc Clin N Am* 1995;5:537-44.
18. Rice TW, Zuccaro GJ, Adelstein DJ, et al. Esophageal carcinoma: depth of tumor invasion is predictive of regional lymph node status. *Ann Thorac Surg* 1998;65:787-92.
19. Shami VM, Villaverde A, Stearns L, et al. Clinical impact of conventional endosonography and endoscopic ultrasound-guided fine-needle aspiration in the assessment of patients with Barrett's esophagus and high-grade dysplasia or intramucosal carcinoma who have been referred for endoscopic ablation therapy. *Endoscopy* 2006;38:157-61.

The Thoracic Surgery Foundation for Research and Education

In 2007 the Thoracic Surgery Foundation for Research and Education (TSFRE) recognized a significant milestone. It was 15 years ago that the Foundation was established by the four leading American thoracic surgical associations, AATS, STS, W TSA, and STSA, to respond to the decrease in research funding from the federal government and institutions for education and research in thoracic surgery. Fifteen years later, these challenges continue!

Since TSFRE's inception, *funding cutting edge research* has been the hallmark of our mission. Over the past 15 years, TSFRE has recognized the following accomplishments:

- Awarding 85 research grants, fellowships, and career development awards, contributing significantly to the progress being made in cardiothoracic research.
- Cultivating partnerships with the National Heart, Lung and Blood Institute (NHLBI) and the National Cancer Institute (NCI); increasing the dollars available to support cardiothoracic research.
- Funding over \$7 million in peer reviewed research!

There has been tremendous expansion in TSFRE's *educational programs* as well.

- 192 Alley-Sheridan Scholars have attended the Health Policy and Leadership program offered through Harvard University and Brandeis University. This program has had a profound impact upon the hundreds of surgeons who have attended and gained invaluable

insight into the public policy process of the US health care system.

- A *Visioning Simulation Conference* was held this past April to provide a forum for leaders in thoracic surgery and invited simulation experts to discuss our shared vision for development and use of simulation in education and certification.
- TSFRE has supported the Thoracic Surgery Directors Association (TSDA) with a contribution of \$50,000 in 2007 and will continue to do so for the next 2 years. These unrestricted funds were granted in response to the TSDA's urgent request to financially support its current programs and its continued efforts to develop core curriculums that will emphasize the significant challenges facing today's residents.

Over the past 15 years, TSFRE has become a pivotal force for the growth and vitality of our specialty and its role is increasing, particularly in the areas of research, academic career development, and postgraduate education. The philanthropic participatory index for members of the Foundation's founding organizations is important as these surgeons know that giving begins at home and TSFRE is their home for research and education. Foundation supporters—through donations or networking—can have a significant impact on the future of cardiothoracic surgery and the welfare of our patients.

If you would like to make a pledge or receive more information about giving to TSFRE, please visit www.TSFRE.org or call Donna Kohli, TSFRE Executive Director, at 978-927-8330.